

# EFECTO DE *Microcystis aeruginosa* EN ÓRGANOS Y TEJIDOS DE POSTLARVAS DE CAMARÓN BLANCO (*Litopenaeus vannamei*) EN AGUA A BAJA SALINIDAD

## *Effect of Microcystis Aeruginosa on Organs and Tissues of White Shrimp (Litopenaeus vannamei) Postlarvae in Low-Salinity Water*

María Soledad Morales-Covarrubias<sup>1\*</sup>, Rosalba Alonso-Rodríguez<sup>2</sup>, José Antonio Velázquez-Garay<sup>1</sup>, Ana María Guadalupe Flores-Chavarría<sup>2</sup> and Alejandro Federico Alva-Martínez<sup>3</sup>

<sup>1</sup>Centro de Investigación en Alimentación y Desarrollo, A. C. Unidad Mazatlán en Acuicultura y Manejo Ambiental. Apdo. Postal 711, Mazatlán, Sin., México. C. P. 82000. <sup>2</sup>Unidad Académica Mazatlán. Instituto de Ciencias del Mar y Limnología, Universidad Nacional Autónoma de México, Apdo. Postal 811, C. P. 82000. <sup>3</sup>Departamento El Hombre y su Ambiente, Universidad Autónoma Metropolitana. Unidad Xochimilco. 04960. Calzada del Hueso 1100, Colonia Villa Quietud, Delegación Coyoacán, D. F., México. \*Corresponding author: Telephone: 00526699898700 marisol@ciad.mx

### ABSTRACT

In eutrophic waters during cyanobacterial bloom lysis, a blend of cyanobacterial toxins and other compounds are released into the water, affecting aquatic communities. This research investigated the effects of toxic cyanobacteria. For this purpose, intact cells from a natural cyanobacterial bloom were taken, and the colonies were disaggregated by ultrasound for 3 minutes. Histological analysis of exposed shrimps revealed lesion development in antennal gland, gills, hepatopancreas, lymphoid organ, muscle and dorsal cecum in *Litopenaeus vannamei* postlarvae, such kind of lesions may interfere with food absorption, respiration, excretion, locomotion and mortality. Hence, *Microcystis aeruginosa* blooms in shrimp ponds may jeopardize the culture by mortality and slowing shrimp growth rate. The acute test with postlarvae of the white shrimp were effective in indicating the toxicity of cyanobacteria and in prognosticating the toxic effects of cyanobacterial blooms, at least on some usual components of the aquatic community, such crustaceans and micro crustaceans.

**Key words:** Crustaceans; *Microcystis aeruginosa*; histological damage, cyanobacteria; *Litopenaeus vannamei*; shrimp culture.

### RESUMEN

En aguas eutrofizadas durante la lisis de células procedentes de floración de cianobacterias, se liberan en el agua una mezcla de toxinas de cianobacterias y otros compuestos afectando a las comunidades acuáticas. El objetivo de este trabajo fue investigar los efectos tóxicos de *Microcystis aeruginosa* en postlarvas de camarón blanco *Litopenaeus vannamei*. Para ello, se tomaron células intactas de una floración natural y las colonias se disgregaron con ultrasonido durante 3 minutos. El análisis histológico de los camarones expuestos a *M. aeruginosa* reveló lesiones en glándula antenal, branquias, hepatopáncreas, órgano linfóide, músculo y el ciego dorsal en postlarvas *L. vannamei*, este tipo de lesiones puede interferir en la absorción de los nutrientes, respiración, excreción, locomoción y causar mortalidad debido a los daños. Por lo tanto, floraciones de *M. aeruginosa* en estanques de cultivo de camarón pueden poner en peligro el cultivo causando crecimiento lento, asfixia y mortalidad. El ensayo de toxicidad aguda utilizando *M. aeruginosa* en postlarvas de camarón blanco fue eficaz en sus objetivos. Con estos resultados se puede pronosticar los efectos tóxicos de las floraciones de esta cianobacteria en algunos de los componentes habituales de la comunidad acuática como crustáceos y micro crustáceos.

**Palabras clave:** Crustáceos; *Microcystis aeruginosa*; daños histológicos; cianobacteria; *Litopenaeus vannamei*, cultivo de camarón.

## INTRODUCTION

The presence of cyanobacteria in reservoirs, lakes, ponds and rivers is worldwide environmental health issue because some cyanobacterial strains produce toxins, as well as taste and odor compounds, as secondary metabolites under particular growth conditions [42, 43]. Several genera of cyanobacteria, such as *Microcystis*, *Anabaena*, and *Oscillatoria* produce a family of microcystins of at least 50 tumor-promoting hepatotoxins [6, 10, 21]. Microcystin-LR (MC-LR), which is the most commonly reported as hepatotoxin is regarded as one of the most toxic microcystins.

Levels as low as one part per billion of certain cyanotoxins (e.g. microcystins and nodularins) have been associated with nonlethal acute or chronic effects in humans, and their monitoring and control, especially in domestic water supplies, is recommended [44]. Most common cyanotoxins exert their effect (neurotoxic and hepatotoxic) upon ingestion; others have been detected only because of their action on cell cultures (cytotoxins), and still others because they may exert a noxious effect on external or exposed tissues, such as the eye or epidermis after contact. One example of this latter case is a debromoaplysiatoxin produced by *Schizothrix calcicola* which upon contact causes "swimmers itch" and eye irritation and, if ingested, may fever symptoms, dizziness, fatigue, and acute gastroenteritis [27, 29].

Association with other cyanophytes considered as assemblages, particularly with *Lyngbya majuscula* and *S. calcicola* produces both lipid-soluble and water-soluble toxins [13, 14, 30]. Together they generate a number of metabolites, including lyngbyastatin-1 and dolastatin-2 that have been shown as potent disrupters of cellular microfilament networks and feeding deterrents. All these substances could explain some of the fish and cultured shrimp mortalities associated with cyanobacterial blooms [2, 8, 9, 13, 19, 30, 33, 35, 39, 40]. The inland production of shrimp is one alternative for diversification of traditional agriculture where using low salinity water from different sources like saline aquifers [28] estuaries, lagoons and rivers when viable low salinity waters are available [12]. The species of shrimp which has shown an adequate acclimatization for inland production is *L. vannamei*, which could inhabit waters that range in salinity from 1 to 40 [5, 38]. In the present study, the effects of toxic cyanobacteria from Chapultepec Lake, Mexico were investigated by performing, short-term acute toxicity tests on white shrimp (*L. vannamei*) postlarvae in low-salinity water, using a natural cyanobacterial bloom. The main objective was to evaluate the possible effects of *Microcystis aeruginosa* on the invertebrate *L. vannamei*.

## MATERIALS AND METHODS

### Sampling of cyanobacteria

Material from cyanobacterial scum was collected with a 20 µM-mesh phytoplankton net in August 2013 at Chapultepec Lake, México. The cyanobacteria *M. aeruginosa* was dominant in the

field at this time. Natural bloom material was kept in refrigeration (Model 5308, ult350-10-A-Thermo, Fisher Scientific, USA) at 4 °C until analysis maintained.

### Preparation of cyanobacteria

For disaggregate the colonies 40 mL *M. aeruginosa* scum was suspended in 100 mL distilled water and sonicated (Model 250-D, Branson, USA) for 3 minutes (min) to and after was accounted in Sedgewick-Rafter chamber (Model S50, PYSE-SGI Limited, United Kingdom). This material was used for exposure experiment.

### Organisms

Two hundred healthy postlarvae (0.32- 0.7 g) white shrimp were obtained from a commercial hatchery in the State of Sinaloa, México. The postlarvae were acclimated in 40 liters (L) container for 5 days (d) with aeration through an airstone, connected to an air hose, and to a 2.5 HP air blower (Gast IMX model R4110-2 USA), and water quality was maintained by siphoning solid wastes (faeces and uneaten food) twice daily and by exchanging 10% of the water in each aquarium once a day before starting the bioassay. The water parameters were salinity 2; oxygen 7.0 to 8.0 mg/L; pH 7.5 to 8.0; ammonia concentration <0.1 mg/L; a 13 hours (h) daylight and 11 h darkness photoperiod at a 30 °C temperature. Shrimp were fed twice daily with a pelleted shrimp feed (35% protein, PURINA®).

### Shrimp assay

For an acute toxicity evaluation, 20 mL ( $100.8 \times 10^6$  cell mL<sup>-1</sup>) of the cyanobacteria sample was poured in 4 L aquarium in triplicate (at a final concentration of 25, 208 cell mL<sup>-1</sup>). Previously fed (2 h) postlarvae (42 organisms per 4 L aquarium with three replicates and one control) were exposed to cyanobacteria concentrations for 48 h under dim light and constant airing. Each aquarium was individually aerated through an air stone, connected to an air hose and to a 2.5 HP blower water quality was reached by siphoning solid wastes (feces and uneaten food) twice on a daily basis, and by performing a 5% water exchange once a day in each aquarium.

### Histological analysis

The cephalothorax and abdominal region of each live and dying shrimp were excised. The tissues were fixed in a Davidson's fixative (Alcohol-formalin-acetic acid solution (AFA) for 36 h [24] followed by the regular histological process and Haematoxylin-Eosine (H-E) staining [24]. Anatomical, histological, and pathological nomenclatures for normal and disease shrimp were performed according to Bell & Lightner [4] and Hasson *et al.* [15]. Slides were analyzed with a light microscope Olympus BX-60-Japan and objectives of 4x, 10x, 40x, 60x 100x. and photographed using a digital camera (Olympus-Infinity 5.0-Japan).

### Toxin analysis

An ELISA immunoassay microcystins/nodularins was performed for analysis of water (Abraxis LLC No. 5200, batch

number 13C1239), following the instructions included in the kit. The detection limit based in MC-LR is 0.10 ppb ( $\mu\text{g/L}$ ). Samples were diluted to obtain more accurate results (1, 1:10, 1:100 and 1:1000) and submitted to ultrasonic bath (sonicator: ColePalmer Instruments Co., USA) sonicated at 20 kHz 50 Wml<sub>1</sub> for 3 min for cell disruption.

## RESULTS AND DISCUSSION

### ELISA method

The standard curve with %B/Bo from each standard (6) versus the corresponding microcystins concentration was plotted. The %B/Bo for the controls and samples, were obtained by interpolation using the standard curve ( $r^2=0.99$ ) and expressed in ppb of microcystins and nodularins. The concentration of the positive control (0.78 ppb) was within the range given by the method 0.75 ppb ( $\pm 25\%$ ). The concentration of MC-LR found in the sample of the lake was 1,020 ppb ( $\mu\text{g MC-LR L}^{-1}$ ) determined from the dilution 1:1000. The cell toxicity was 0.01 pg MC-LR cell<sup>-1</sup>.

### Shrimp assays

Toxin concentration at which the larvae were exposed was 0.005 mg MC-LR L<sup>-1</sup>. The shrimps showed severe stress, a reduced feeding activity, empty gastrointestinal tract, whitish, 'milky' appearance of the stomach, whitish hepatopancreas, lethargy, and soft shells compared to unexposed animals during the test period (48 h). The toxin concentration treatment presented 76 (60.31%) shrimp mortalities after 30 h of inoculation.

### Histological analysis

The lesion development, as described here, is generalized from samples taken from study at various times.

**Antennal gland:** showed alterations such as atrophy of antennal gland tubule, pyknotic nuclei, haemocytic infiltration and hemolymph were observed (FIG. 1).

**Gills:** showed severe edema, pyknotic nuclei, hyperplasia, haemolymph cell infiltration as well as thickened and enlarged gill chambers and lamellar sinuses at were observed (FIG. 2).

**Hepatopancreas:** the proximal tubule epithelium decreased in height from its normal columnar height to a low cuboidal, and this was accompanied by a marked reduction in the relative abundance of secretory and lipid vacuoles (FIG. 3), heavy haemocytic infiltration in the interstitial sinuses (FIG. 3), pyknotic nuclei, rounded up and sloughed from their basement membrane, and finally underwent cytolysis. The lumina of hepatopancreatic tubules in regions in which necrosis was occurring were typically filled with sloughed epithelial cells that contained pyknotic or karyorrhectic nuclei, some necrotic tubules and melanin-like area in the tissue.

**Muscle:** muscular tissues showed pathological alterations; included degeneration in muscles with infiltration and aggregations of hemocytes between them and focal areas of necrosis. Also, atrophy of muscle bundles, edema, hyaline degeneration and splitting of muscle fibers (FIG. 4).

**Lymphoid organ:** The lobules, lymphoid tubules were disorganized and had lost the normal appearance, and parts of the tubules were lymphoid spheroids that lacked a lumen when compared to the normal lymphoid tubule. The lymphoid spheroids could be classified into three types: Spheroid type 1 was a lightly basophilic, homogeneous mass. Cells in the spheroid contained hypertrophic nuclei with few or no cytoplasmic vacuoles. Spheroid type 2, considered to develop from type 1, appeared more basophilic in staining, and was fully encapsulated with a fibrous connective sheet and a layer of cells with flat nuclei. There were increased numbers of apoptotic cells that contained intensely basophilic nuclei and a moderate number of cytoplasmic vacuoles. Spheroid type 3, contained the most basophilic cells and was encapsulated by thick fibrous connective tissue. Most cells in this type of spheroid appeared highly vacuolated with apoptotic nuclei with dense and marginalized chromatin.

**Midgut:** Reduction in height of the mucosa, epithelium columnar decreased and had lost the normal appearance, hyperplasia and hemocytic inflammation (FIG. 5).

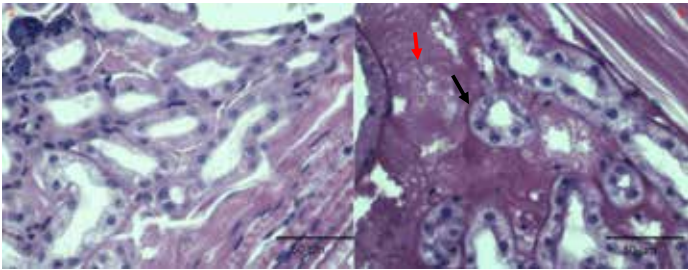
**Dorsal Cecum:** Lost the epithelial folds, necrosis of the epithelium, heavy hemocytic inflammation and atrophy (FIG. 6).

Cyanobacteria are the main components of phytoplankton in Chapultepec Lake, visible blooms were present in this lake, the dominant species found were *M. aeruginosa*, *M. panniformis*, *M. prototocystis* and others with a concentration of toxin from 4.9 to 78 mg MC-LR L<sup>-1</sup> [43] which is lower than that found in this study. The concentration found in this study represents 1000 times greater than the permissible limit for microcystin drinking water [44]. The cell toxicity is lower in this study than found by Zimba *et al.* [46] of 2 pg cell<sup>-1</sup>.

In the present study it was investigated acute effect of white shrimp experimentally exposed to *M. aeruginosa*. Shrimp exposure to cyanobacteria could reduce growth and cause mortality in shrimp farms, during intensive blooms of hepatotoxin production, shrimps can accumulate toxins [18].

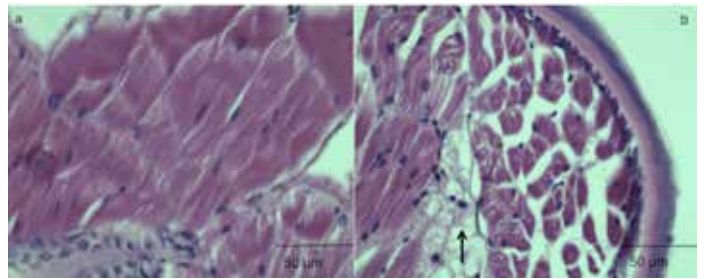
Some alterations as toxicity effects of *M. aeruginosa* on mortality and lesion development in antennal gland, gills, hepatopancreas, lymphoid organ, muscle and dorsal cecum were observed in *L. vannamei* postlarvae.

Mortality was 60% and Lawrence *et al.* [22] considered normal less than 20%, for shrimp postlarvae. The histological effects observed in the hepatopancreas of the organisms grown in hypo-osmotic conditions (controls) are similar to those reported by Li *et al.* [23], who found that the number of B and R cells was altered at a salinity of 3. The F cells are the main site for synthesis of digestive enzymes and accumulate in B cells accelerate the mobilization of nutrients in the hepatopancreas tubules when there is an increased demand of energy to adapt to environmental stress. Thus, the decrease of these and of R cells might be due to utilization of their nutrient reserves, because of the increased energy demand for osmoregulation [1]. *M. aeruginosa* which produces distinctive hepatotoxicity of microcystins has been well studied in the last few years [3,17,37].



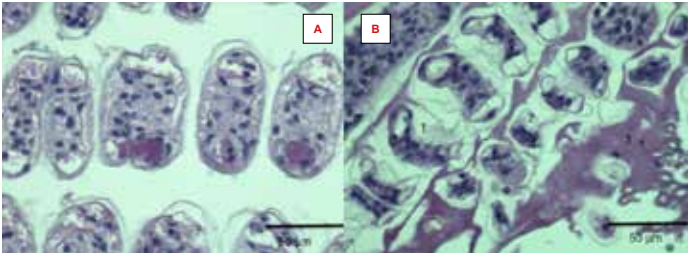
**FIGURE 1A:** LONGITUDINAL SECTION OF ANTENNAL GLAND TUBULES CONTROL SHRIMP TISSUE SHOWING NORMAL ANTENNAL GLAND TUBULES. (H&E). BARR 50 μM.

**FIGURE 1B:** LONGITUDINAL SECTION OF ANTENNAL GLAND TUBULES, SHOWING ATROPHY OF ANTENNAL GLAND TUBULE (BLACK ARROW), PYKNOTIC NUCLEI, AND SEVERE HAEMOLYMPH INFILTRATION (RED ARROW). (H&E). BARR 50 μM



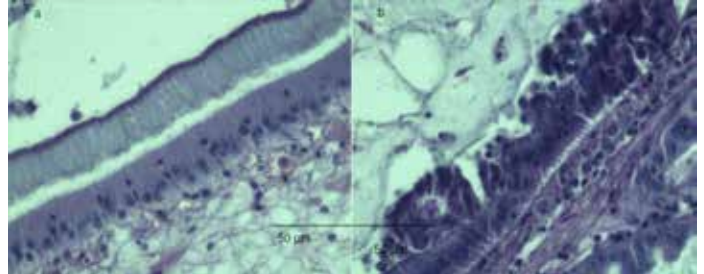
**FIGURE4:** LONGITUDINAL SECTION OF CONTROL SHRIMP TISSUE SHOWING NORMAL MUSCLE.

**FIG. 4B:** LONGITUDINAL SECTION OF MUSCLE SHOWED FOCAL AREAS OF NECROSIS (ARROW), ATROPHY OF MUSCLE BUNDLES AND HAEMOLYMP INFILTRATION. (H&E). BARR 50 μM.



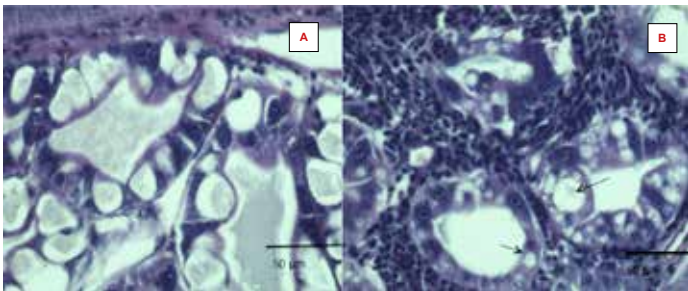
**FIGURE 2A:** LONGITUDINAL SECTION OF CONTROL SHRIMP TISSUE SHOWING NORMAL GILLS.

**FIGURE 2B:** LONGITUDINAL SECTION OF GILLS SHOWED SEVERE EDEMA (1), NECROSIS (2), HYPERPLASIA AND HAEMOLYMP INFILTRATION (3). (H&E). BARR 50 μM.



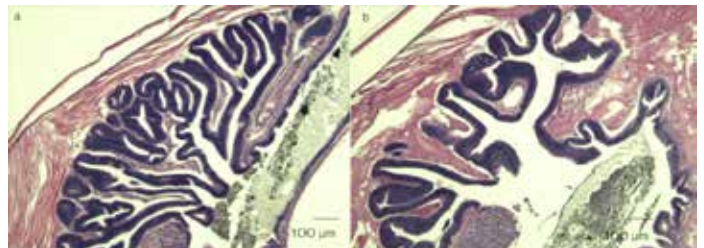
**FIGURE 5A:** LONGITUDINAL SECTION OF CONTROL SHRIMP TISSUE SHOWING NORMAL MIDGUT

**FIGURE 5B:** LONGITUDINAL SECTION OF MIDGUT SHOWED EPITHELIUM COLUMNAR DECREASED AND HAD LOST THE NORMAL APPEARANCE, HYPERPLASIA AND HEMOCYTIC INFLAMMATION. (H&E). BARR 50 μM



**FIGURE 3A:** LONGITUDINAL SECTION OF CONTROL SHRIMP TISSUE SHOWING NORMAL HEPATOPANCREATIC TUBULES OF *Litopenaeus vannamei* AT THE BEGINNING OF THE EXPERIMENT. OBSERVE THE HIGH NUMBER OF B (BLISTER-LIKE) CELLS (ARROWS).

**FIGURE 3B:** LONGITUDINAL SECTION HEPATOPANCREATIC TUBULES OF SHRIMP SUBMITTED TO FORCED-INGESTION OF *MICROCYSTIS AERUGINOSA* FOR 30 HOURS, OBSERVE ATROPHY TUBULES, HEAVY HEMOCYTIC INFILTRATION IN THE INTERSTITIAL SINUSES, PYKNOTIC NUCLEI AND LOW NUMBER OF B (ARROWS). (H&E). BARR 50 μM.



**FIGURE 6A:** LONGITUDINAL SECTION OF CONTROL SHRIMP TISSUE SHOWING NORMAL CAECUM

**FIGURE 6B:** LONGITUDINAL SECTION OF CAECUM WITH LOST THE EPITHELIAL FOLDS, HEMOCYTIC INFLAMMATION AND ATROPHY. (H&E). BARR 50 μM

Several authors reported histopathological alterations in hepatocytes after microcystin exposure [7, 10, 11, 37], due to destruction of the cytoskeleton caused by an increased level of protein phosphorylation. Hooser *et al.* [16] observed dissociation and necrosis of hepatocytes after microcystins acute exposure. In the present study, hepatopancreas from postlarvae shrimp exposed to *M. aeruginosa* (cyanotoxins) showed heavy haemocytic infiltration, some necrotic tubules and melanin-like area in the tissue. This last response is a possible result of an immune reaction.

Crustaceans are considered as carrying a simple and primitive immune system, where the cellular reactions for defense frequently are followed by a process of melanization [41]. The function of melanin in immune responses of arthropods is still not clearly elucidated, although it was postulated that this compound could act as a reactive oxygen species (ROS) scavenger [31, 36]. Parallel to the toxin exposure, a possible effect of starvation on hepatopancreas histology also should be considered, since a significant reduction in B cell number in control shrimp after 2 days of experiment was observed.

Papathanassiou and King [34] evaluated ultrastructural changes in the hepatopancreatic cells of the common prawn *Palaemon serratus* induced by 56 h of starvation. These authors registered a lower number of secretory cells (B cells) in the tubules of starved specimens. It was also observed that starvation induced by moulting also results in a lower number of B cells in the hepatopancreas of *Penaeus semisulcatus* [1, 34].

In the present study, it was observed that the number of F cells was not affected by toxin exposure, whereas a lower number of B cells were clearly evident in postlarvae shrimp after 2 d of experiment. Interestingly, it has been established that cells from hepatopancreas of the crab *Carcinus maenas* express P-glycoprotein (P-gp) in transitional F and B cells, suggesting that these cells are specialized for accumulation and elimination of toxic compounds [20, 36]. The existence of P-gp in crustacean hepatopancreas opens the possibility of aquatic animals employing this mechanism to eliminate cyanotoxins (or its conjugates). The histological effects observed in the lymphoid organ of the organisms acutely exposed to *M. aeruginosa* were the presence of numerous lymphoid spheroids that were formed during the course of toxin exposure. Hasson *et al.* [15] observed the presence of three types of spheroidal masses after infection with Taura syndrome virus and proposed that they played roles in sequestering and finally eliminating viruses.

In the gills, the haemocytic congestion observed can be considered response to tissue damage caused by the pollutant. Haemocytic congestion can account for another possible role for gills during intoxication, namely a route of elimination for toxic substances, as explained by Lowe [26]. Haemocytic congestions gave rise to acute respiratory distress. This coupled with reduction in surface area of the respiratory barrier of gill filament and the inhibition of enzyme mitochondrial transport systems led to the

inevitable death of aquatic animals. The crustacean gill is a multi-functional organ, and it is the site of a number of physiological processes, including ion transport, which is the basis for hemolymph osmoregulation; acid-base balance and ammonia excretion. The gill is also the site by which many toxic metals are taken up by aquatic crustaceans, and thus it plays an important role in the toxicology of these species.

In the antennal gland, the hemocytic congestion observed can be considered responses to intoxication. The function of the antennal gland in penaeid shrimp has been associated with the differences in the osmolarity and sodium and chloride concentration between hemolymph and urine [45]. Lesions in the midgut like those described here have been previously described in blue shrimp (*L. stylirostris*), exposed to *Spirulina subsalsa* [25] and pink shrimp (*P. duorarum*), exposed to cadmium [32]. Hemocytic lesions of this type probably occur as a result of the action of several types of organic and inorganic toxins on the portions of the shrimp digestive tract that is without a lining cuticle.

## CONCLUSIONS

Acute toxicity test with *L. vannamei* shrimp postlarvae indicated that toxins released from the cyanobacterial bloom from Chapultepec Lake were potentially capable of producing alteration and severity damage in antennal gland, gills, hepatopancreas, lymphoid organ, muscle and dorsal cecum caused killing of *L. vannamei* shrimp postlarvae and would therefore have adverse effects on other aquatic invertebrates. Thus, blooms of cyanobacteria may cause major disruptions of the aquatic ecosystem, in addition to severe negative effects on wildlife and humans. The toxicity effects of *M. aeruginosa* homeostasis breakdown, which in turn affects important physiological and biological functions including the mobilization of nutrients in the hepatopancreas tubules, respiration and acid-base balance; and ammonia excretion. Considering the prevailing situation of shrimp aquaculture practice in Northwest Mexico, the possibility of a sudden *M. aeruginosa* bloom that would affect the animal's growth, thus inducing lower yields or prolonging the necessary culture period to reach a commercial size, is a risk that needs to be faced. The authors also believe that shrimp farms may become more susceptible to infectious agents that promote high mortalities as a result of a *M. aeruginosa* bloom. Therefore, in order to prevent the collapse of the culture, monitoring of noxious and toxic cyanobacteria blooms is highly recommended.

## ACKNOWLEDGEMENT

This study was supported by Centro de Investigación en Alimentación y Desarrollo, A.C. (CIAD) grant 2017710219-MCMS and Fundación Produce Colima grant 06-2011-0018. Instituto de Ciencias del Mar y Limnología grant 326-ARR.

**BIBLIOGRAPHIC REFERENCES**

- [1] AL-MOHANNA, S. Y.; NOTT, J. D. Functional cytology of the hepatopancreas of *Penaeus semisulcatus* (Crustacea: Decapoda) during the moult cycle. **Mar. Biol.** 101:503–44. 1989.
- [2] BANNER, A. H. Marine Toxins from the Pacific. Advances in the investigation of fish toxins. **Anim. Toxic.** 4: 157-165. 1966.
- [3] BEATTIE, K. A.; RESSLER, J.; WIEGAND, C.; KRAUSE, E.; CODD, G. A.; STEINBERG, C. E. W.; PFLUGMACHER, S. Comparative effects and metabolism of two microcystins and nodularin in the brine shrimp *Artemia salina*. **Aquacult. Toxic.** 62: 219-226. 2003.
- [4] BELL, T. A.; LIGHTNER, D. V. A handbook of normal penaeid shrimp histology. **World Aquacult. Soc.** 114 pp. 1988.
- [5] BRAY, W. A.; LAWRENCE, A. L.; LEUNG-TRUJILLO, J. R. The effect of salinity on growth and survival of *Penaeus vannamei*, with observations on the interaction of IHNV virus and salinity. **Aquacult.** 122: 133–146. 1994.
- [6] CARMICHAEL, W. Health effects of toxin-producing cyanobacteria: “The CyanoHABs”. Human Ecology. Risk Assessment. **Internal. J.** 7: 1393-1407. 2001.
- [7] CARMICHAEL, W. Cyanobacterial secondary metabolites—the cyanotoxins. **J. of Applied Bacteriol.** 72: 445–459. 1992.
- [8] CASÉ, M.; LEÇA, E.E.; LEITÃO, S.N.; SANT’ANNA, E.E.; SCHWAMBORN, R.; DE MORAES JUNIOR, A.T. Plankton community as an indicator of water quality in tropical shrimp culture ponds. **Mar. Pollut. Bull.** 56 (7): 1343–1352. 2008.
- [9] CORTÉS-ALTAMIRANO, R.; LICEA-DURAN, S. Florecimientos de microalgas nocivas en estanques de cultivo semi-intensivo de camarón en México. **Rev. Latin. de Microbiol.** 41: 157-166. 1999.
- [10] DAWSON, R. M. The toxicology of microcystins. **Toxicol.** 36: 953-962. 1998.
- [11] FALCONER, I. R.; HUMPAGE, A. Tumour promotion by cyanobacterial toxins. **Phycol.** 35: 74–79. 1996.
- [12] FLAHERTY, M.; SZUSTER, B.; MILLER, P. Low Salinity inland shrimp farming in Thailand. **Ambio.** 29: 174-179. 2000.
- [13] HARRIGAN, G. G.; YOSHIDA, W. Y.; MOORE, R. E.; NAGLE, D. G.; PARK, P. U.; BIGGS, J.; PAUL, V. J.; MOOBERRY, S. L.; CORBETT, T. H.; VALERIOTE, F. A. Isolation, structure determination, and biological activity of dolastin 12 and lyngbyastatin 1 from *Lyngbya majuscula* *Schizothrix calcicola* cyanobacterial assemblages. **J. Nat. Prod.** 61: 1221-1225. 1998.
- [14] HARRIGAN, G. G.; YOSHIDA, W. Y.; MOORE, R. E.; NAGLE, D. G.; PARK, P. U.; BIGGS, J.; PAUL, V. J. Tumonoic acids, novel metabolites from a cyanobacterial assemblage of *Lyngbya majuscula* and *Schizothrix calcicola*. **J. of Nat. Prod.** 62: 464-467. 1999.
- [15] HASSON, K. W.; LIGHTNER, D. V.; MOHNEY, L. L.; REDMAN, R. M.; WHITE, B. M. Role of lymphoid organ spheroids in chronic Taura syndrome virus (TSV) infections in *Penaeus vanamei*. **Dis. Aquat. Org.** 38:93–105. 1999.
- [16] HOOSER, S. B.; BEASLEY, V. R.; LOVELL, R. A.; CARMICHAEL, W. W.; HASCHEK, W. M. Toxicity of microcystin-LR, a cyclic heptapeptide hepatotoxin from *Microcystis aeruginosa*, to rats and mice. **Vet. Pathol.** 26:246-252. 1989.
- [17] JANG, M. H.; HA, K.; LUCAS, M. C.; JOO, G. J.; TAKAMURA, N. Changes in microcystin production by *Microcystis aeruginosa* exposed to phytoplanktivorous and omnivorous fish. **Aquat. Toxicol.** 68: 51-59. 2004.
- [18] KANKAAPÄÄ, H. T.; HOLLYDAY, J.; SCHRÖDER, H.; GOODDARD, T. J.; VON FISTER, R.; CARMICHAEL, W. W. Cyanobacteria and prawn farming in northern New Wales, Australia—a case study on cyanobacterial diversity and hepatotoxin bioaccumulation. **Toxicol. Applied Pharmac.** 203: 243-256. 2005.
- [19] KEHHAVANATH, P.; BEVERIDGE, M. C. M.; BAIRD, D. J.; LAWTON, L. A.; NIMMO, A.; CODD, G.A. The functional grazing response of a phytoplanktivorous fish *Oreochromis niloticus* to mixtures of toxic and non-toxic strains of the cyanobacterium *Microcystis aeruginosa*. **J. Fish Biol.** 45: 123 – 129. 1994.
- [20] KÖHLER, H. R.; TRIEBSKORN, R. Assessment of the cytotoxic impact of heavy metals on soil invertebrates using a protocol integrating qualitative and quantitative components. **Biomarkers.** 3(2): 109-127. 1998.
- [21] LAM, A.; PREPAS, E. In situ evaluation of options for chemical treatment of hepatotoxic cyanobacterial blooms. **Can. J. Fish. Aquat. Sci.** 54: 1736-1742. 1997.
- [22] LAWRENCE, A. L.; CASTILLE, F. L.; SPEED, M.; MCKEE, D.A.; PAGE, K.O. A simple stress test for *Penaeus vannamei* postlarvae. **Aquacult.** 165: 233– 242. 1999.
- [23] LI, E.; CHEN, L.; ZENG, C.; YU, N.; XIONG, Z.; CHEN, X.; QIN, J. G. Comparison of digestive and antioxidant enzymes activities, haemolymph oxyhemocyanin contents and hepatopancreas histology of white shrimp, *Litopenaeus vannamei*, at various salinities. **Aquacult.** 274: 80-86. 2008.
- [24] LIGHTNER, D. V. A handbook of shrimp pathology and diagnostic procedures for diseases of cultured penaeid shrimp, **World Aquacult. Soc.** Louisiana, USA. Pp 1-198. 1996.
- [25] LIGHTNER, D. V. Possible toxic effects of the marine blue-green alga, *Spirulina subsalsa*, on the blue shrimp, *Penaeus stylirostris*. **J. Invertebr. Pathol.** 32: 139- 150. 1978.3

- [26] LOWE, D. M. Cytological and cytochemical measurements. Histopathological conditions. In: **the effects of stress and pollution on marine animals**. Bayne, B.L. (Ed.). Praeger Publishers New York. Pp 51-63. 1985.
- [27] LYPPY, E. C.; ERB, J. Gastrointestinal illness at Sewickley, Pa. **J. Am. Water Works Assoc.** 68: 606-610. 1976.
- [28] MCGRAW, W. J.; DAVIS, D. A.; TEICHERT-CODDINGTON, D.; ROUSE, D. B. Acclimation of *Litopenaeus vannamei* postlarvae to low salinity: Influence of age, salinity endpoint, and rate of salinity reduction. **J. World Aquacult. Soc.** 33: 78-84. 2002.
- [29] MYNDERSE, J. S.; MOORE, R. E.; KASHIWAGI, M.; NORTON, T. R. Antileukemia activity in the oscillatoriae: isolation of debromoaplysiatoxin from *Lyngbya*. **Sci.** 196: 538-540. 1977.
- [30] NAGLE, D. G.; PAUL, V. J. Chemical defense of a marine cyanobacteria bloom. **J. Exp. Mar. Biol. Ecol.** 225: 29-38. 1998.
- [31] NAPPI, A. J.; VASS, E. Melanogenesis and the generation of cytotoxic molecules during insect cellular immune-reactions. **Pigment. Cell Res.** 6: 117-126. 1993.
- [32] NIMMO, D. R.; LIGHTNER, D. V.; BAHNER, L. Effects of cadmium on the shrimps, *Penaeus duorarum*, *Palaemonetes pugio* and *Palaemonetes vulgaris*. In "**Physiological Responses of Marine Biota to Pollutants**". Academic Press New York. Pp 131-183. 1977.
- [33] OVERSTREET, R. M. Parasites of some penaeid shrimp with emphasis on reared hosts. **Aquacult.** 2: 105-140. 1973.
- [34] PAPATHANASSIOU, E.; KING, P. E. Effects of starvation on the fine structure of the hepatopancreas in the common prawn *Palaemon serratus* (Pennat). **Compar. Biochem. and Physiol A.** 77: 243-249. 1984.
- [35] PÉREZ-LINARES, J.; CADENA, M.; RANGEL, C.; UNZUETA-BUSTAMANTE, M. L.; OCHOA, J. L. Effect of *Schizothrix calcicola* on white shrimp *Litopenaeus vannamei* (*Penaeus vannamei*) postlarvae. **Aquacult.** 218:55-65. 2003.
- [36] PINHO, G. L. L.; MOURA DA ROSA, C.; MACIEL, F. E.; BIANCHINI, A.; YUNES, J. S.; PROENÇA, L. A. O.; MONSERRAT, J. M. Antioxidant responses and oxidative stress after microcystin exposure in the hepatopancreas of an estuarine crab species. **Ecotox. Environ. Safe.** 61: 353-360. 2005.
- [37] PINHO, G. L. L.; MOURA DA ROSA, C.; YUNES, J. S.; LUQUET, C. M.; BIANCHINI, A.; MONSERRAT, J. M. Toxic effects of microcystins in the hepatopancreas of the estuarine crab *Chasmagnathus granulatus* (Decapoda, Grapsidae). **Comp. Bioch. Physiol.** 135: 459-468. 2003.
- [38] ROY, L. A.; DAVIS, D. A.; SAOUD, I. P.; BOYD, C. A.; PINE, H. J.; BOYD, C. E. Shrimp culture in inland low salinity waters. **Rev. Aquacult.** 2: 191-208. 2010.
- [39] YOO, R. S.; CARMICHAEL, W. W.; HOEHN, R. C.; HRUDEY, S. E. Cyanobacterial (blue-green algal) toxins: a resource guide. American Waterworks Association. Research Foundation Denver. CO. USA. Pp 229. 1992.
- [40] SMITH, O. Toxic effect of blooms of marine species of oscillatoriales of farmed prawns (*Penaeus monodon*, *Penaeus japonicus*) and brine shrimp (*Artemia salina*). **Toxicon.** 34: 857-869. 1996.
- [41] SÖDERHÄLL, K.; CERENIUS, L. Crustacean immunity. **Ann. Rev. Fish. Dis.** 2: 3-23. 1992.
- [42] TEIXEIRA, M. R.; SOUSA, V.; ROSA, M. J. Investigating dissolved air flotation performance whit cyanobacterial cells and filaments. **Water Res.** 44: 3337-3344. 2010.
- [43] VASCONCELOS, V.; MARTINS, A.; VALE, M.; ANTUNES, A.; AZEVEDO, J.; WELKER, M.; LÓPEZ, O.; MONTEJANO, G. First Report on occurrence of microcystins in planktonic cyanobacteria from Central Mexico. **Toxicon.** 56:425-431. 2010.
- [44] WORLD HEALTH ORGANIZATION (WHO). Cyanobacterial toxins: Microcystin-LR in drinking-water. Documento de referencia para la elaboración de las Guías de la OMS para la calidad del agua potable. Ginebra (Suiza), Organización Mundial de la Salud (WHO/SDE/WSH/03.04/57). Pp 1-64. 2003.
- [45] XUGANG, H.; GUANGFU, H.; GUANGTAO, L. Comparative study in functional morphology of antennary gland of pacific white shrimp, *Litopenaeus vannamei*, reared under various salinity condition. E. Zhu and S. Sambath (Eds.): **Information Technical and Agricultural Engineering**. AISC 134. Pp 151-159. 2012.
- [46] ZIMBA, V. P.; CAMUS, A.; ALLEN, H. E.; BURKHOLDER, M. J. Co-occurrence of white shrimp, *Litopenaeus vannamei*, mortalities and microcystin toxin in a southeastern USA shrimp facility. **Aquacult.** 261: 1048-1055. 2006.